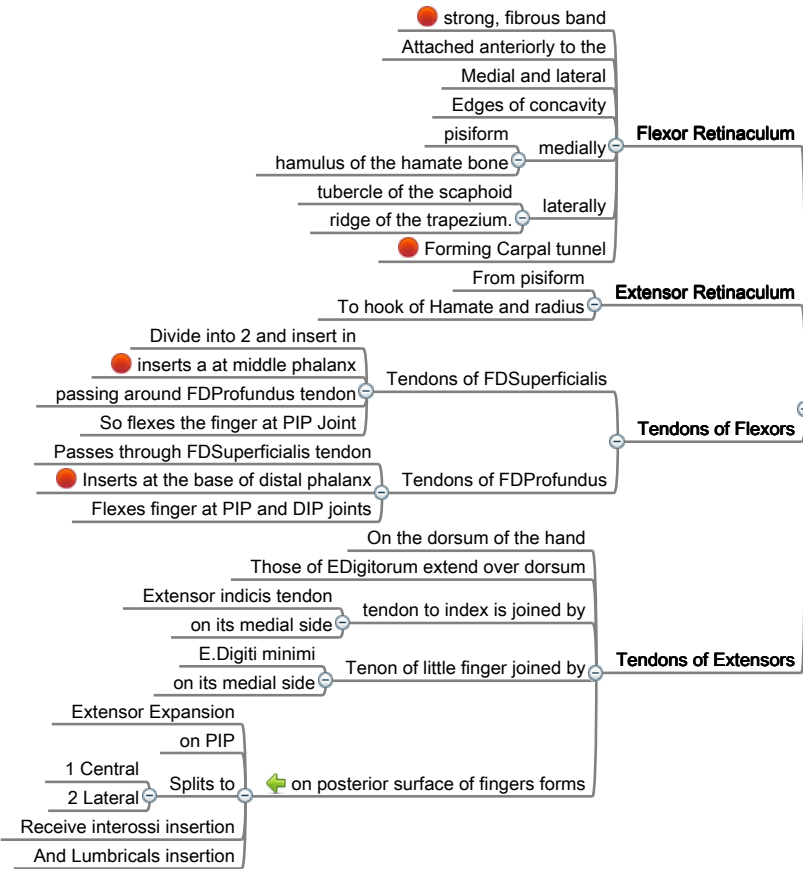
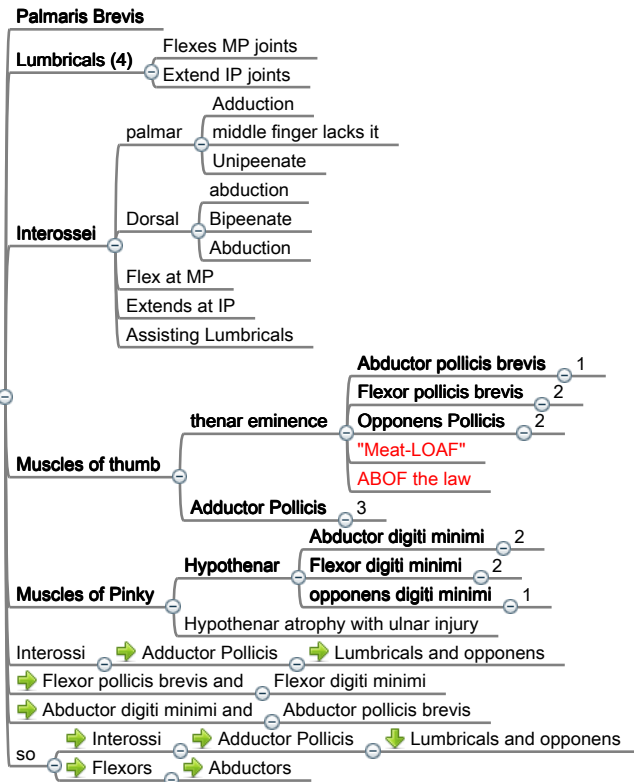


# Hand

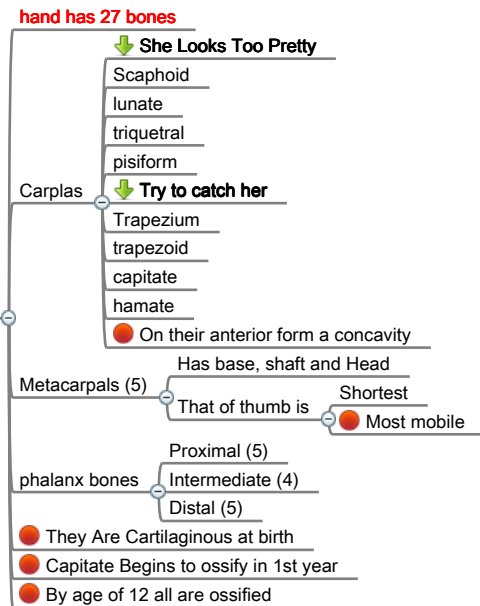
## Ligaments



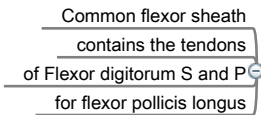
## Muscles



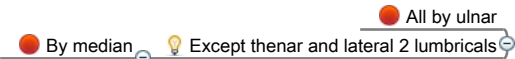
## Bones



## Synovial flexor sheaths



## Nerve supply



## Palmar Aponeurosis

