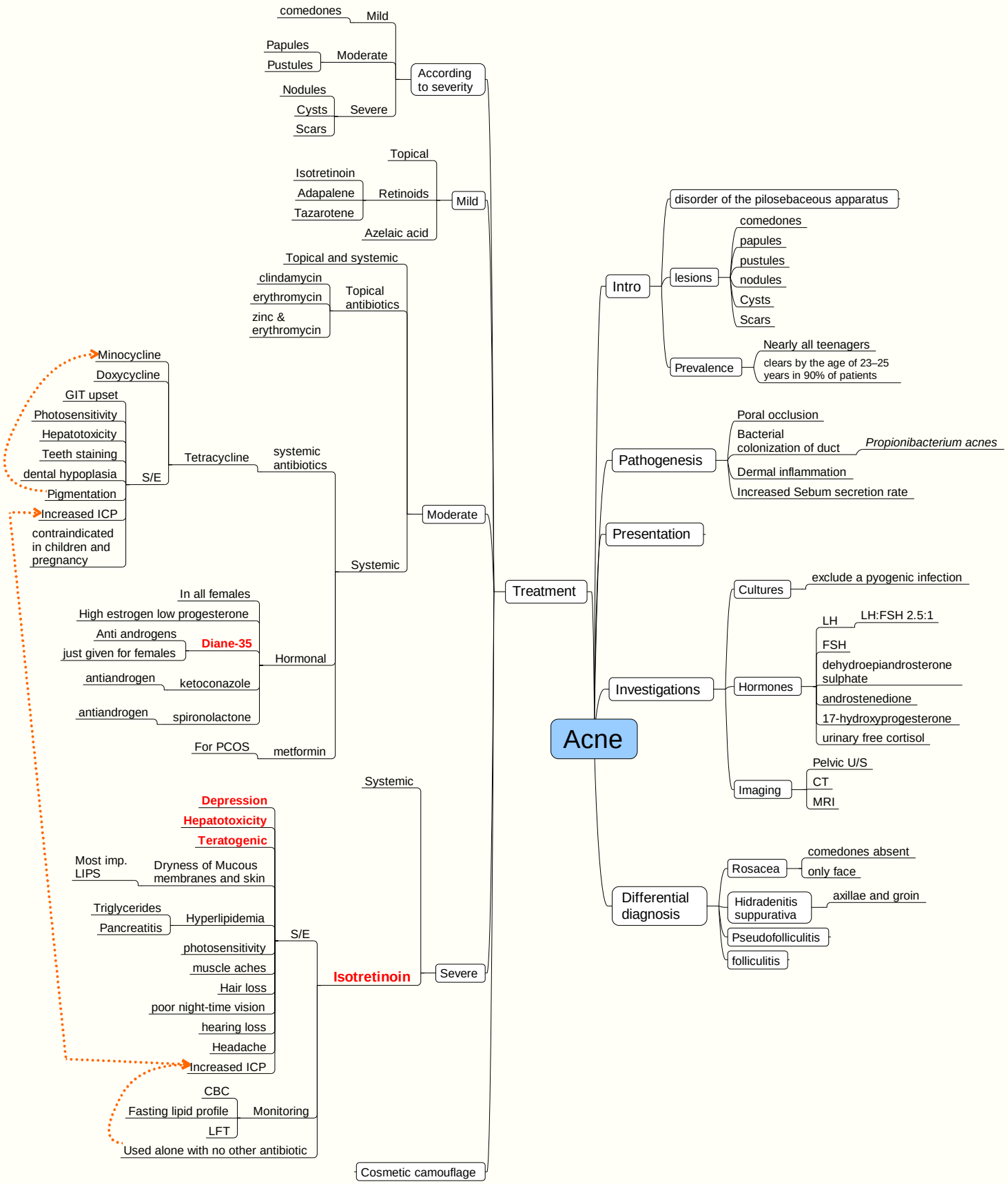
Acne
Intro
disorder of the pilosebaceous apparatus
lesions
comedones
papules
pustules
nodules
Cysts
Scars
Prevalence
Nearly all teenagers
clears by the age of 23–25 years in 90% of patients
Pathogenesis
Poral occlusion
Bacterial colonization of duct
Propionibacterium acnes
Dermal inflammation
Increased Sebum secretion rate
Presentation
Investigations
Cultures
exclude a pyogenic infection
Hormones
LH
LH:FSH 2.5:1
FSH
dehydroepiandrosterone sulphate
androstenedione
17-hydroxyprogesterone
urinary free cortisol
Imaging
Pelvic U/S
CT
MRI
Differential diagnosis
Rosacea
comedones absent
only face
Hidradenitis suppurativa
axillae and groin
Pseudofolliculitis
folliculitis
Treatment
According to severity
Mild
comedones
Moderate
Papules
Pustules
Severe
Nodules
Cysts
Scars
Mild
Topical
Retinoids
Isotretinoin
Adapalene
Tazarotene
Azelaic acid
Moderate
Topical and systemic
Topical antibiotics
clindamycin
erythromycin
zinc & erythromycin
Systemic
systemic antibiotics
Tetracycline
Minocycline
Doxycycline
S/E
GIT upset
Photosensitivity
Hepatotoxicity
Teeth staining
dental hypoplasia
Pigmentation
Increased ICP
contraindicated in children and pregnancy
Hormonal
In all females
High estrogen low progesterone
Diane-35
Anti androgens
just given for females
antiandrogen
ketoconazole
antiandrogen
spironolactone
For PCOS
metformin
Severe
Systemic
Isotretinoin
S/E
Depression
Hepatotoxicity
Teratogenic
Dryness of Mucous membranes and skin
Most imp. LIPS
Hyperlipidemia
Triglycerides
Pancreatitis
photosensitivity
muscle aches
Hair loss
poor night-time vision
hearing loss
Headache
Increased ICP
Monitoring
CBC
Fasting lipid profile
LFT
Used alone with no other antibiotic
Cosmetic camouflage