

# Inflammatory Bowel Disease

## IBD

### An Introduction

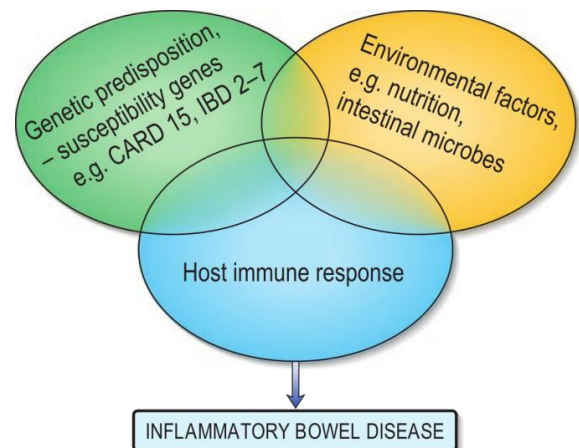
Inflammatory bowel disease is a chronic inflammatory disorder characterized by a protracted relapsing and remitting course, usually extending over years. It is classically sub divided into three separate diseases, the **Ulcerative colitis (UC)**, **Crohn's disease (CD)**, and **Indeterminate Colitis**. They are diagnosed by a set of clinical, endoscopic, and histological characteristics, but no single finding is absolutely diagnostic for one disease or the other.

### Epidemiology

The incidence of IBD varies within different geographic areas. CD and UC both occur at the highest incidence in Europe, the United Kingdom, and North America. Incidence rates range from 2.2 to 14.3 cases per 100,000 person-years for UC and from 3.1 to 14.6 cases per 100,000 person-years for CD. The peak age of onset of UC and CD is between **15 and 30 years**. A second peak occurs between the ages of **60 and 80**. The male to **female** ratio for UC is 1:1 and for **CD** is 1.1–1.8:1. UC and CD have two- to fourfold increased frequency in Jewish populations in the United States, and it has higher incidence rate among **Ashkenazi Jews**. The highest mortality is during the first years of disease and in long-duration disease due to the risk of colon cancer.

### Pathogenesis

Although the aetiology of IBD is unknown, it is becoming clear that IBD represents the outcome of three essential interactive co-factors: **genetic susceptibility**, the **environment** and **host immune response**. With the environmental factors representing both the **local** microenvironment (enteric microflora) and also the **nutritional** environment.



## Genetic susceptibility

*Familial:* A positive family history is the largest independent risk factor for the disease.

*Genetic:* There is increased concordance for the disease (CD more than UC) in monozygotic twins in comparison with dizygotic twins who demonstrated familial aggregation. Crohn disease and ulcerative colitis have been linked to specific major histocompatibility complex class II alleles. Ulcerative colitis has been associated with HLA-DRB1, whereas HLA-DR7 and DQ4 alleles are associated with approximately 30% of Crohn disease.

## Environmental factors

### *Hygiene theory*

Good domestic hygiene has been shown to be a risk factor for CD but not for UC. Thus poor and large families living in crowded conditions with no tap or hot water and consuming contaminated food have a lower risk of developing CD.

*H. pylori* sero-prevalence is high in developing countries but low in patients with CD.

A 'clean' environment may not expose the intestinal immune system to pathogenic or non-pathogenic microorganisms, particularly helminthic parasites, and therefore be 'untrained' to confront minor infections. Helminth infections are associated with a type 2 helper T cell response (Th2), which would counterbalance the type-1 helper T cell response (Th1) that is characteristic of CD. If such a mechanism is operative, it would explain why there is a frequent association of a recent intestinal infection with the first presentation and subsequent flare-ups of CD.

### *Lifestyle*

- *Breast feeding:* may provide protection against inflammatory bowel disease developing in offspring.
- *Nutritional factors:* Many foods and food components have been suggested to play a role in the aetiopathogenesis of IBD (e.g. high sugar and fat intake) but unfortunately the results of numerous studies have been equivocal.
- *Smoking:* Patients with CD are more likely to be smokers, and smoking has been shown to exacerbate CD. By contrast, there is an increased risk of UC in non- or ex-smokers and nicotine has been shown to be an effective treatment of UC.
- *Adverse life events and psychological factors:* such as chronic stress and depression seem to increase relapses in patients with quiescent disease.

### *Appendicectomy*

Is 'protective' for the development of UC, particularly if performed for appendicitis or for mesenteric lymphadenitis before the age of 20. It also influences the clinical course of UC, with a lower incidence of colectomy and need for immunosuppressive therapy. By contrast, appendicectomy may increase the risk of development of CD and may result in more aggressive disease.

### *Intestinal microflora*

Evidence supports a hypothesis that IBD is characterized by an overaggressive immune response to luminal bacterial antigens and other products, occurring against a background of genetic susceptibility.

### **Host immune response**

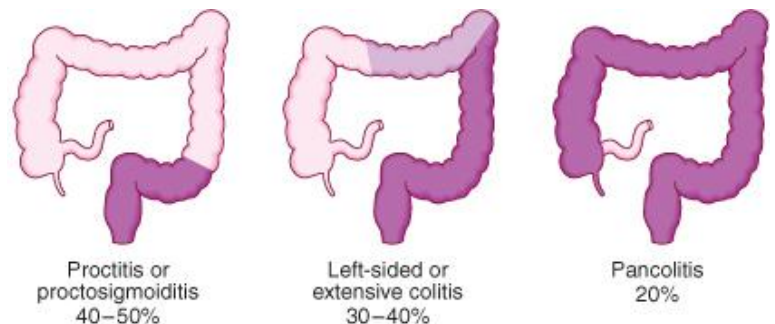
It is currently thought that IBD results from a defective mucosal immune system producing an inappropriate response to luminal antigens, such as bacteria which enter the intestine via a leaky epithelium.

## **Ulcerative Colitis**

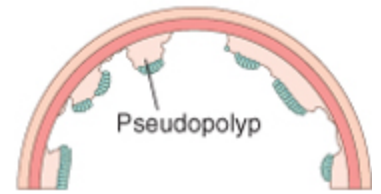
Ulcerative colitis is a chronic, recurrent disease characterized by diffuse mucosal inflammation involving only the colon. Ulcerative colitis invariably involves the rectum and may extend proximally in a continuous fashion to involve part or the entire colon.

### **Pathology**

UC is characterized by inflammation limited to the mucosa and submucosa of the colon, Inflammation invariably involves the rectum (**proctitis**). It may spread proximally to involve the sigmoid colon (**proctosigmoiditis**) and in a minority the whole colon is involved (**pancolitis**). When the whole colon is involved, the inflammation extends 1–2 cm into the terminal ileum in 10–20% of patients. This is called **backwash ileitis** and is of little clinical significance.



Inflammation is confluent and is more severe distally. In long-standing pancolitis the bowel becomes shortened, narrowed and 'pseudopolyps' develop; these represent normal or hypertrophied residual mucosa within areas of atrophy.



Patients with fulminant disease can develop a toxic colitis or megacolon where the bowel wall thins and the mucosa is severely ulcerated; this may lead to perforation.

*Histologically*, the inflammatory process is limited to the mucosa and superficial submucosa, and spares the deeper layers of the bowel wall except in fulminant disease. Both acute and chronic inflammatory cells infiltrate the lamina propria and the crypts ('cryptitis'). Crypt abscesses are typical. Goblet cells lose their mucus and in long-standing cases glands become distorted. Dysplasia, characterised by heaping of cells within the crypts, nuclear atypia and increased mitotic rate may herald the development of colon cancer.

## Clinical features

The major symptom is **bloody diarrhea**; this diarrhea is often nocturnal and/or postprandial. Other frequent symptoms include tenesmus, passage of mucus, and crampy abdominal pain. The first attack is usually the most severe and thereafter the disease is followed by relapses and remissions. Only a minority of patients have chronic, unremitting symptoms. Emotional stress, intercurrent infection, gastroenteritis, antibiotics or NSAID therapy may provoke a relapse. The clinical features depend upon the site and activity of the disease

*Proctitis* causes rectal bleeding passing fresh blood and mucus discharge that may also be blood-stained; the blood is either mixed with stool or streaked onto the surface of a normal or hard stool. Patients may complain of tenesmus. Some patients pass frequent, small-volume fluid stools, while others are constipated and pass pellety stools. Constitutional symptoms do not occur.

*Proctosigmoiditis* causes bloody diarrhoea with mucus. Almost all patients are constitutionally well but a small minority who have very active, limited disease develop fever, lethargy and abdominal discomfort

*Extensive colitis* causes bloody diarrhoea with passage of mucus. In severe cases anorexia, malaise, weight loss and abdominal pain occur, and the patient is toxic with fever, tachycardia and signs of peritoneal inflammation

The severity of the disease is assessed according to the presence of a combination of signs, symptoms, and investigation results, and the factors used for the assessment include:

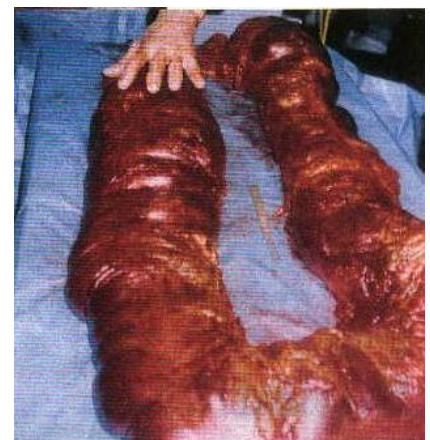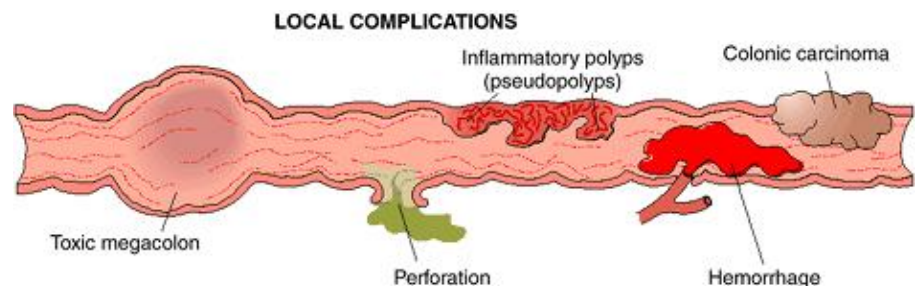
- Bowel movements
- Blood in stool
- Fever
- Tachycardia
- Anemia
- Sedimentation rate
- Endoscopic appearance

And according to the frequency, occurrence, or values of these factors the disease is classified into, mild, moderate, or severe.

## Complications

The most severe complication of ulcerative colitis is **toxic megacolon**, the plain abdominal X-ray shows a dilated thin-walled colon with a diameter of **> 6 cm**; it is gas filled and contains mucosal islands. Associated with worsening of the patient's clinical condition and the development of fever, tachycardia, and leukocytosis. Examination may reveal postural hypotension, tenderness over the distribution of the colon, and absent or hypoactive bowel sounds. Antispasmodics and antidiarrheal agents are likely to initiate or exacerbate toxic megacolon. Deterioration is marked by the development of rebound tenderness, increasing abdominal girth, and cardiovascular collapse. If **perforation** occurs surgical intervention is indicated.

**Strictures** can occur in 5–10% of patients and are always a concern in UC because of the possibility of underlying neoplasia since dysplasia due to chronic inflammation is usually sub-mucosal in UC, and not visible by naked eye in endoscopy.

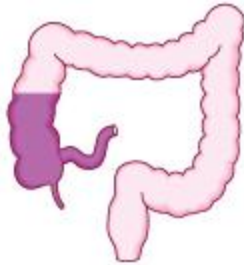

# Crohn's Disease

Crohn disease is a chronic, recurrent disease characterized by patchy transmural inflammation involving any segment of the gastrointestinal tract from the mouth to the anus.

## Pathology

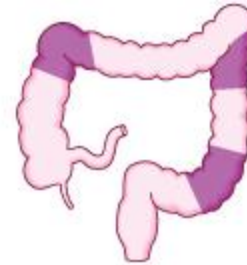40% of patients have small-bowel disease alone, 40–55% has disease involving both the small and large intestines, and 15–



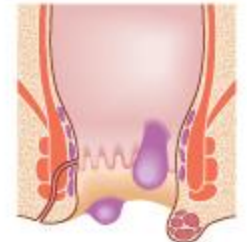Ileal or ileocolonic  
40%



Small intestinal  
30–40%



Crohn's colitis  
c. 20%



Perianal disease alone  
< 10%

25% has colitis alone. The sites most commonly involved, in order of frequency, are terminal ileum and right side of colon, colon alone, terminal ileum alone, ileum and jejunum. Unlike UC the rectum is often spared in CD.

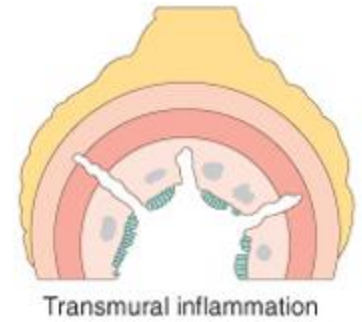
Characteristically, the **entire** wall of the bowel is oedematous and thickened. There are **deep** ulcers which often appear as linear fissures; thus the mucosa between them is described as '**cobblestone**'. Deep ulcers may penetrate through the bowel wall to initiate abscesses or fistulae. **Fistulae** may develop between adjacent loops of bowel or between affected segments of bowel and the bladder, uterus or vagina, and may appear in the perineum.

Characteristically, the changes are **patchy**. Even when a relatively short segment of bowel is affected, the inflammatory process is interrupted by islands of **normal** mucosa and the change from the affected part is abrupt. A small lesion separated in this way from a major area of involvement is referred to as a 'skip' lesion. The mesenteric lymph nodes are enlarged and the **mesentery thickened**. Projections of thickened mesentery encase the bowel ("creeping fat"), and serosal and mesenteric inflammation promotes adhesions and fistula formation.

Active CD is characterized by focal inflammation and formation of **fistula** tracts, which resolve by **fibrosis** and **stricturing** of the bowel. The bowel wall thickens and becomes narrowed and fibrotic, leading to chronic, recurrent bowel **obstructions**.

Perirectal fistulas, fissures, abscesses, and anal stenosis are present in one-third of patients with CD, particularly those with colonic involvement.

Histologically, chronic inflammation is seen through all the layers of the bowel wall (**transmural process**), which is thickened as a result. There are focal aggregates of epithelioid histiocytes, which may be surrounded by lymphocytes and contain giant cells.



Lymphoid aggregates or **microgranulomas** are also seen, and when these are near to the surface of the mucosa they often **ulcerate** to form tiny **aphthous**-like ulcers which are the earliest lesions. These **non-caseating granulomas** appear in all layers of the bowel wall, lymph nodes, mesentery, peritoneum, liver, and pancreas. These are the most characteristic and the most reliable lesions that could differentiate CD from UD, but although these are pathognomonic for CD, these lesions cannot be demonstrated in all patients with CD.

## Clinical features

The major presenting symptoms are **abdominal pain**, **diarrhoea** and **weight loss**. The inflammatory process of CD evolves toward one of two patterns of disease: a **fibrostenotic-obstructing pattern** or a **penetrating-fistulous pattern**

*Ileal Crohn's disease* as the terminal ileum is the most common site of inflammation patients usually present with an episode or recurrent episodes of colicky right lower quadrant **abdominal pain**, which is relieved by defecation. abdominal pain can be due to subacute intestinal obstruction, although an inflammatory mass, intra-abdominal abscess or acute obstruction may be responsible.

Pain is often associated with **diarrhoea** which is **watery** and does not contain blood or mucus. A low-grade **fever** can be also associated at the presentation. Almost all patients **lose weight**. This is usually because they avoid food since eating provokes pain. Weight loss may also be due to malabsorption, which can occur due to loss of digestive and absorptive surface and some patients may present with features of fat, protein or vitamin deficiencies.

Bowel obstruction in CD can take several forms, in the early stages of disease, it can occur as a result of bowel wall edema, during later stages it occurs as a result of chronic inflammation causing fibrostenotic narrowing and stricture.

Patients with **fistulous pattern** of the disease may present with dysuria or recurrent bladder infections or, less commonly, as pneumaturia or fecaluria due to **Enterovesical** fistulas, or with dyspareunia (painful intercourse) or as a feculent or foul-smelling, often painful vaginal discharge due to **Enterovaginal** fistulas, lastly **Enterocutaneous** fistulas can occur too.

*Crohn's colitis* presents in an identical manner to ulcerative colitis, with **bloody** diarrhoea, passage of mucus, abdominal pain and **constitutional** symptoms including lethargy, malaise, anorexia and weight loss. Rectal sparing and the presence of perianal disease are features which favor a diagnosis of Crohn's disease rather than ulcerative colitis. Many patients present with symptoms of both small bowel and colonic disease.

*Perianal disease* affects about one-third of patients with Crohn's colitis and is manifested by incontinence, large hemorrhoidal tags, anal strictures, anorectal fistulae, and perirectal abscesses. A few have **isolated perianal disease**, vomiting from jejunal strictures or severe oral ulceration.

Physical examination often reveals evidence of weight loss, anaemia with glossitis and angular stomatitis. There is abdominal tenderness, most marked over the inflamed area. An abdominal mass due to matted loops of thickened bowel or an intra-abdominal abscess may occur. Perianal skin tags, fissures or fistulae are found in at least 50% of patients.

## Complications

### *Abscesses and Fistulas*

These are products of extension of the transmural inflammation causing mucosal fissuring or ulcer through the intestinal wall and into extraintestinal tissue. Leakage of intestinal contents through a fissure into the peritoneal cavity results in an **abscess**. Abscesses are more common when CD involves the terminal ileum, and the typical clinical manifestation of an intra-abdominal abscess is fever, abdominal pain, tenderness, and leukocytosis. Extension of the inflammatory process through the wall of adjacent viscera or through the abdominal wall to the exterior results in a **fistula**.



### *Obstruction*

**Obstruction** is a common complication of Crohn's disease, particularly in the small intestine, and is a leading indication for surgery. It can be caused by mucosal edema, mucosal scarring, and adhesions.

### *Perianal Disease*

This is an especially difficult complication of Crohn's disease. **Fistulous** openings are most commonly found in the perianal skin but can occur in the groin, the vulva, or the scrotum. The fistulas drain serous or mucous material. If the fistula does not drain freely, there is local accumulation of pus and formation of **perianal abscess**.

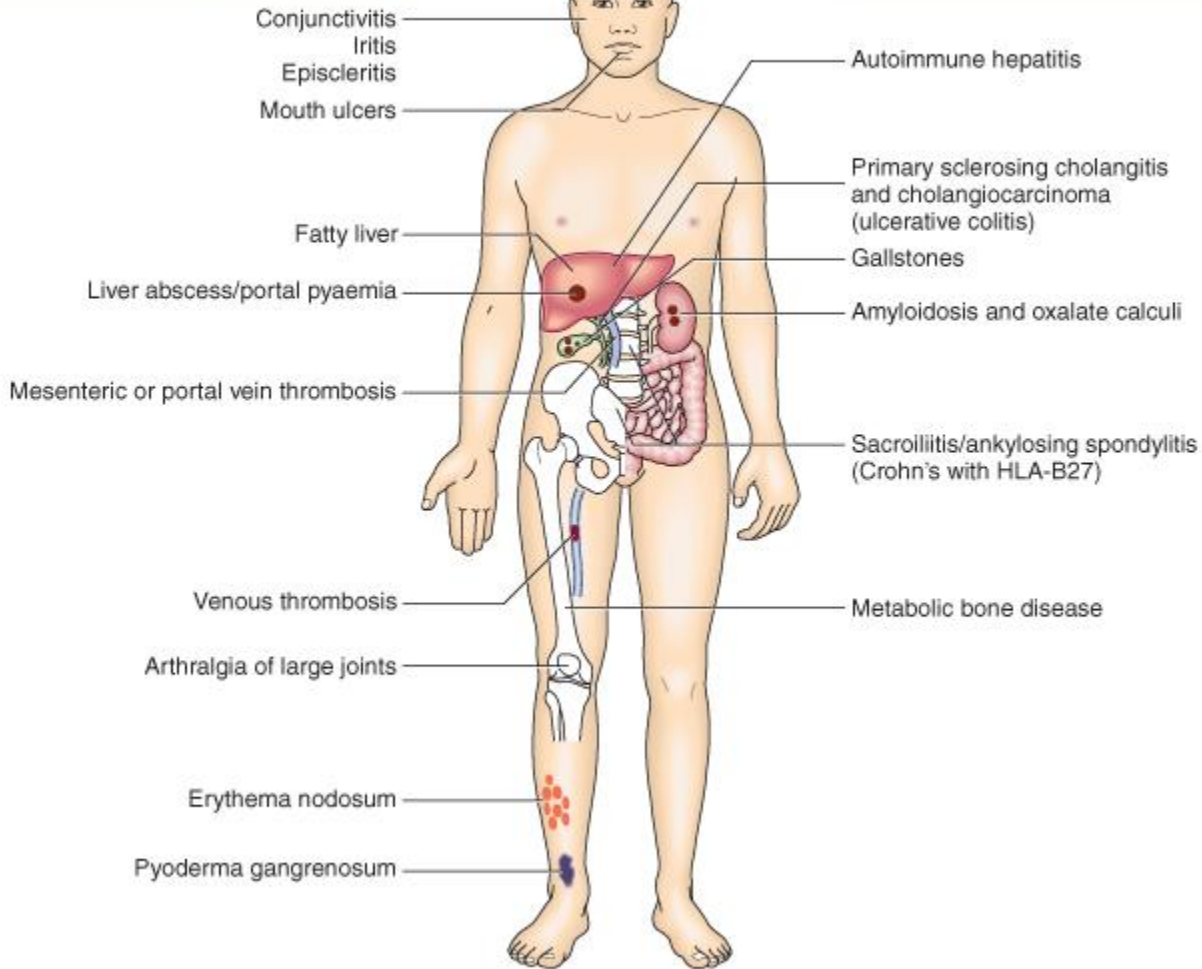
### *Malabsorption and malnutrition*

This is characteristic if the disease involves the small intestine, and disease may presents with any symptom of malabsorbtion, like: anemia, bleeding tendency, ostemalacia, and many more.

# Extraintestinal Manifestations of UC and CD

Occur during the active phase of inflammatory bowel disease

Unrelated to inflammatory bowel disease activity



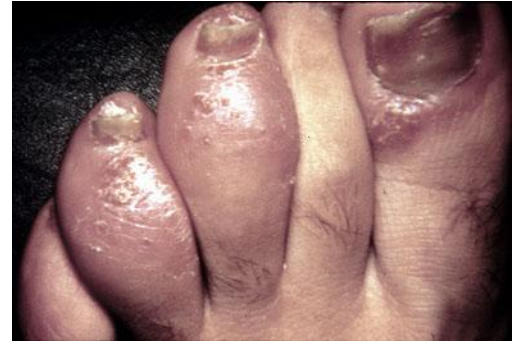The extraintestinal manifestations can be divided into two major groups: (1) those in which the clinical activity follows the activity of the bowel disease and (2) those in which the clinical activity is unrelated to the activity of the bowel disease.

## Arthritis

This is the most common extraintestinal manifestation of IBD, including **colitic arthritis** and **ankylosing spondylitis**.

*Colitic arthritis* is a migratory arthritis that affects the knees, hips, ankles, wrists, and elbows, parallels the course of the bowel disease; successful treatment of the intestinal inflammation results in improvement in the arthritis.

*Ankylosing spondylitis* is characterized by morning stiffness, low back pain, and a stooped posture; it can be relentlessly progressive and crippling, Medical treatment of the IBD and colectomy are not helpful in managing ankylosing spondylitis. Unattended cases of AS that are accompanied by **dactylitis** ("sausage digit" is inflammation of an entire digit) or **enthesitis** (is an inflammation of the point at which a tendon inserts into bone). Patients may present with low back pain of Ankylosing spondylitis years before the onset of IBD. Patients with ankylosing spondylitis have an increased frequency of the HLA-B27 allele and AS is more common in CD.



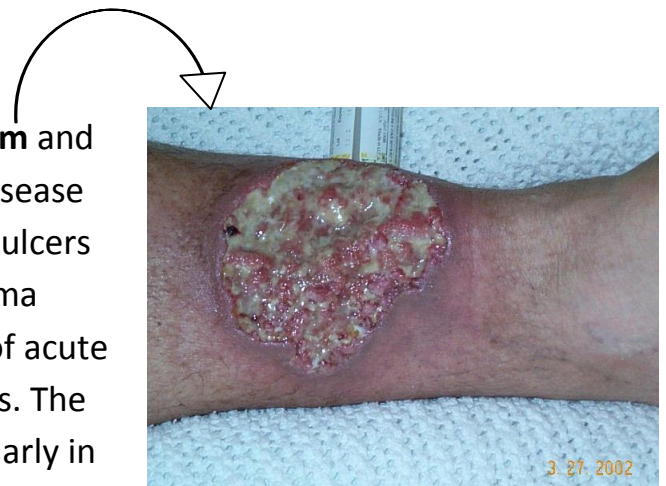
### *Hepatic and Biliary Manifestations*

These include fatty liver, pericholangitis, chronic active hepatitis, cirrhosis, and UC in particular is associated with autoimmune hepatitis. Biliary tract complications are sclerosing cholangitis (ulcerative colitis) and gallstones (Crohn's disease).

*Primary Sclerosing cholangitis* is a chronic cholestatic liver disease marked by fibrosing inflammation of the intrahepatic and extrahepatic bile ducts. Even though it occurs in only 1 to 4% of patients with **ulcerative colitis** and with lower frequency in Crohn's disease, the majority of patients with sclerosing cholangitis have IBD. Colectomy and medical treatment of the bowel disease do not ameliorate the course and PSC can be detected earlier than the IBD or even years after proctocolectomy. It is worth mentioning that PSC can present before IBD manifest, but bear in mind that 70% of patients with PSC have IBD.

### *Dermal Manifestations*

The two common lesions are **pyoderma gangrenosum** and **erythema nodosum**. Pyoderma gangrenosum is a disease that causes tissue to become necrotic, causing deep ulcers that usually occur on the legs. The lesions of pyoderma gangrenosum almost always develop during a bout of acute colitis and generally resolve with control of the colitis. The activity of erythema nodosum, which is seen particularly in association with Crohn's disease in children, follows the activity of the bowel disease. Oral mucosal lesions, seen often in CD and rarely in UC, include aphthous stomatitis.



### *Ocular Manifestations*

These include **uveitis** and **episcleritis** and they require local therapy with corticosteroids and agents that dilate the pupil helps prevent scarring and blindness. Symptoms include ocular pain, photophobia, blurred vision, and headache. **Conjunctivitis** occurs too.

### *Metabolic bone disease*

Patients with IBD are prone to developing **osteopenia**, **osteoporosis** and **fractures**. This is partly a consequence of corticosteroid use, and patients with CD are particularly susceptible to metabolic bone disease, due to the combined effects of malnutrition, malabsorption.

### *Thromboembolic Disorders*

Patients with IBD have an increased risk of both venous and arterial thrombosis even if the disease is not active.

## **Complications common to UC and CD**

Perforation of the small intestine or colon, which can occur without the development of toxic megacolon. And Life-threatening acute haemorrhage due to erosion of a major artery is a rare complication of both UC and CD.

### *Cancer*

Patients with extensive ulcerative colitis have a markedly increased risk for colon cancer in comparison to the general population beginning 8 to 10 years after diagnosis and increasing with time. The risk for malignancy is also a function of the anatomic extent of the disease; the risk is much greater with **pancolitis** than with left-sided disease. Regular surveillance should start after 10 years with colonoscopy done every 2 years, but for patients with pancolitis should undergo regular surveillance to detect early colon cancer usually should start 2 years from diagnosis. The risk for colon cancer in Crohn's colitis is less than in ulcerative colitis but greater than in the general population and this is especially evident in patients with involvement of the colon.

## Diagnosis of UC and CD

First step is patient's medical History and physical examination, the next step is Investigations

### Investigations

#### Crohn's disease

##### *Laboratory investigations*

###### *Blood tests*

- **Anaemia** is common and is usually the normocytic, normochromic anaemia of chronic disease. Deficiency of iron and/or folate also occurs. Despite terminal ileal involvement in CD, megaloblastic anaemia due to B12 deficiency is unusual, although serum B12 levels can be below the normal range.
- Raised ESR and CRP and a raised white cell count.
- Hypoalbuminaemia is present in severe disease.
- Liver biochemistry may be abnormal.
- Blood cultures are required if septicaemia is suspected.
- Serological tests. pANCA antibody is negative. The reverse is true in UC but the clinical value of this test is limited. ASCA (Anti-saccharomyces cerevisiae antibodies) antibody is positive.

###### *Stool cultures*

These should always be performed on presentation if diarrhea is present.

###### *Imaging*

###### *Endoscopic features of CD*

**Colonoscopy** is performed if colonic involvement is suspected except in patients presenting with severe acute disease. The findings vary from mild **patchy** superficial (aphthoid) ulceration to more widespread larger and deeper ulcers producing a **cobblestone** appearance, characteristics finding on colonoscopy include: earliest macroscopic findings of colonic CD are **aphthous ulcers**, we also find **rectal sparing, fistulas, cobblestone appearance and skip lesions**.



**Upper endoscopy** is useful in diagnosing gastroduodenal involvement in patients with upper tract symptoms. **CT enterography** can be used instead of endoscopy and colonoscopy yet they have the advantage that it can be used for diagnosis and treatment, as biopsy can be taken and during colonoscopy ileal or colonic **strictures** may be dilated with balloons.

#### *Barium follow-through examination or CT scan*

Always be performed in patients suspected of having CD to visualize lesions in the small intestine, since CD involves the whole GIT system. The findings include an asymmetrical alteration in the mucosal pattern with deep **ulceration**, and areas of narrowing or **stricturing**.

#### *X-ray*

Done in patients presenting acutely with suspected intestinal obstruction

#### *High-resolution ultrasound and CT scanning*

These are both helpful techniques in defining thickness of the bowel wall and mesentery as well as intra-abdominal and para-intestinal **abscesses**.

#### *Endoanal ultrasound and MRI*

These can be used to evaluate perianal disease.

#### *Capsule endoscopy*

This is used to visualize the small intestine, which will be involved in CD.

#### *Biopsy*

Characterized by transmural inflammation, fissuring, granulomas.

# Ulcerative Colitis

## Laboratory investigations

### Blood tests

- In moderate to severe attacks iron deficiency **anaemia** is commonly present and the **white cell** and **platelet** counts are raised.
- The **ESR** and **CRP** are often raised; liver biochemistry may be abnormal, with hypoalbuminaemia occurring in severe disease.
- **pANCA** may be positive. **ASCA** (Anti-saccharomyces cerevisiae antibodies) antibody is negative.

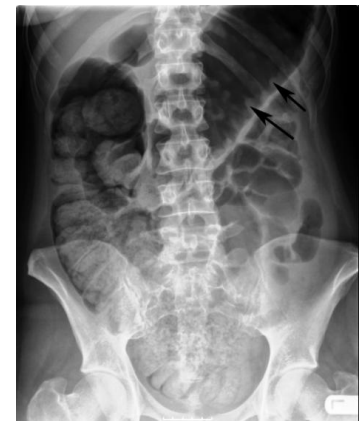### Stool cultures

These should always be performed to exclude infective causes of colitis. It is worth mentioning that *C. difficile*, and *amoeba* can present with similar picture to UC.

## Imaging

### X-ray

Is the best for assessment of colonic dilation in toxic megacolon



### Colonoscopy

Sigmoidoscopy is used to assess disease activity and is often performed before treatment. If the patient is not having an acute flare, colonoscopy is used to assess disease extent and activity.

UC is characterized by continuous lesions through involved segments, lesions are superficial and most commonly involving the rectum, in chronic cases there is formation of pseudopolyps.

## Biopsy

Typically involves distortion of intestinal crypt architecture, inflammation of crypts (cryptitis), frank crypt abscesses.

## Differential Diagnosis of UC and CD

All causes of diarrhoea should be excluded and stool cultures should always be performed. Crohn's disease should be considered in all patients with evidence of malabsorption.

### Infectious Diseases

This may be due to **bacterial, fungal, viral, or protozoal** infection.

- **Campylobacter** colitis can mimic the endoscopic appearance of severe UC and can cause a relapse of established UC.
- **Salmonella** can cause watery or bloody diarrhea, nausea, and vomiting.
- **Shigellosis** causes watery diarrhea, abdominal pain, and fever followed by rectal tenesmus and by the passage of blood and mucus per rectum.
- **Yersinia enterocolitica** infection occurs mainly in the terminal ileum and causes mucosal ulceration, neutrophil invasion, and thickening of the ileal wall.
- Other bacterial infections that may mimic IBD include **C. difficile**, which

presents with watery diarrhea, tenesmus, nausea, and vomiting; and **E. coli**, three categories of which can cause colitis. These are enterohemorrhagic, enteroinvasive, and

Diseases that Mimic IBD		
<b>Infectious Etiologies</b>		
<b>Bacterial</b> <div style="border: 1px solid black; padding: 2px;"> <i>Salmonella</i>  <i>Shigella</i>  Toxigenic <i>Escherichia coli</i>  <i>Campylobacter</i>  <i>Yersinia</i>  <div style="border: 1px solid black; padding: 2px;"><i>Clostridium difficile</i></div> </div> Gonorrhoea <i>Chlamydia trachomatis</i>	<b>Mycobacterial</b> <div style="border: 1px solid black; padding: 2px;">Tuberculosis</div> <i>Mycobacterium avium</i>  <b>Parasitic</b> <div style="border: 1px solid black; padding: 2px;">Amebiasis</div> <i>Isospora</i> <i>Trichuris trichura</i> Hookworm <i>Strongyloides</i>	<b>Viral</b> Cytomegalovirus Herpes simplex HIV  <b>Fungal</b> Histoplasmosis <i>Candida</i> <i>Aspergillus</i>
<b>Noninfectious Etiologies</b>		
<b>Inflammatory</b> Appendicitis <div style="border: 1px solid black; padding: 2px;">Diverticulitis</div> Diversion colitis Collagenous/lymphocytic colitis <div style="border: 1px solid black; padding: 2px;">Ischemic colitis</div> <div style="border: 1px solid black; padding: 2px;">Radiation colitis/enteritis</div> Solitary rectal ulcer syndrome Eosinophilic gastroenteritis Neutropenic colitis Behçet's syndrome Graft-versus-host disease	<b>Neoplastic</b> Lymphoma Metastatic carcinoma Carcinoma of the ileum Carcinoid Familial polyposis	<b>Drugs and Chemicals</b> NSAIDs Phosphasoda Cathartic colon Gold Oral contraceptives Cocaine Chemotherapy

**Note:** NSAIDs, nonsteroidal anti-inflammatory drugs.

Those in   are especially important to consider



enteroadherent E. coli, all of which can cause bloody diarrhea and abdominal tenderness.

- Gastrointestinal involvement with **mycobacterial** infection occurs primarily in the immunosuppressed patient but may occur in patients with normal immunity.
- ***Entamoeba histolytica*** or related species infect about 10% of the world's population; symptoms include abdominal pain, tenesmus, frequent loose stools containing blood and mucus, and abdominal tenderness.

## Noninfectious Diseases

- **Diverticulitis** can be confused with CD clinically and radiographically. Both diseases cause fever, abdominal pain, tender abdominal mass, leukocytosis, elevated ESR, partial obstruction, and fistulas.
- **Ischemic colitis** is commonly confused with IBD. The ischemic process can be chronic and diffuse, as in UC, or segmental, as in CD.

## Treatment

Treatment of IBD involves medical and surgical modalities, so the Best treatment depends upon a team approach involving physicians, surgeons, radiologists and dietitians. Both ulcerative colitis and Crohn's disease are life-long conditions and have psychosocial implications; counsellors and patient support groups have important roles in education, reassurance and coping. The key aims are to:

- Treat acute attacks
- Prevent relapses
- Detect carcinoma at an early stage
- Select patients for surgery.

### Supportive treatment and Symptomatic relief in acute attacks

- Antidiarrheal agents (e.g. loperamide)
- Antipyretics
- Analgesics
- Intravenous fluids to correct dehydration along with nutritional support, usually as enteral rather than intravenous feeding, for malnourished patients.

### Remission induction

- Ulcerative colitis
  - Aminosalicylates
  - Corticosteroids (systemic or enema)
  - Ciclosporin
- Crohn's disease
  - Aminosalicylates
  - Corticosteroids
  - Ciclosporin
  - Anti-TNF drugs (e.g. Infliximab)

## Maintaining Remission

- We use the same drugs, except for Corticosteroids since they can cause iatrogenic Cushing's syndrome, and osteoporosis.
- And in CD the most effective step is smoking cessation.

## Treatment of complications

- Crohn's disease
  - **Strictures** of CD can be treated by endoscopic procedures without surgeries.
  - **Fistulas** are treated with anti-TNF drugs, and can be managed with surgery.

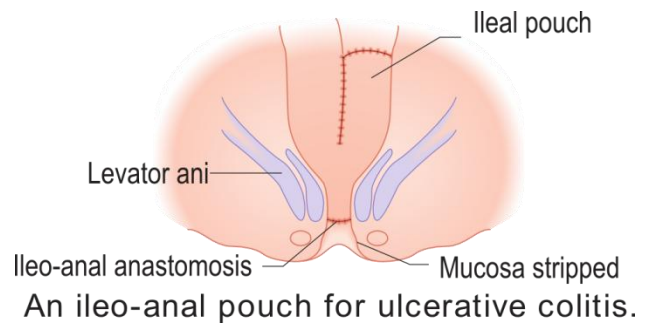
## Surgery

The most important indication is Failure of medical therapy. And timing of surgery is very important.

- Crohn's disease

Operations are often necessary to deal with **fistulae**, **abscesses** and **perianal disease**, and may also be required to relieve small or large bowel obstruction.

Surgery is **not** curative and disease recurrence is the rule. Surgical intervention should therefore be as conservative as possible in order to minimise loss of viable intestine and to avoid creation of a short bowel syndrome.



Around 80% of Crohn's patients undergo surgery at some stage, and **70% of these require more than one operation** during their lifetime. Clinical recurrence following resectional surgery is present in 50% of all cases at 10 years.

- Ulcerative colitis

Surgery involves removal of the entire colon and rectum and cures the patient. The choice of procedure is either panproctocolectomy with ileostomy, or proctocolectomy with ileal-anal pouch anastomosis. It is usually indicated in case of failure of medical therapy, mechanical complications, or cancer, and in cases of cancer or failure of therapy the whole colon is removed and the patient is **cured**.

## Prognosis

Life expectancy in patients with IBD is now **similar** to that of the general population. Although many patients require surgery and admission to hospital for other reasons, the majority have an excellent work record and pursue a normal life. Around 90% of ulcerative colitis patients have intermittent disease activity, whilst 10% have continuous symptoms.

Different Clinical, Endoscopic, and Radiographic Features		
	<b>Ulcerative Colitis</b>	<b>Crohn's Disease</b>
<b>Clinical</b>		
Gross blood in stool	Yes	Occasionally
Mucus	Yes	Occasionally
Systemic symptoms	Occasionally	Frequently
Pain	Occasionally	Frequently
Malabsorption	No	Yes
Abdominal mass	Rarely	Yes
Significant perineal disease	No	Frequently
Fistulas	No	Yes
Small-intestinal obstruction	No	Frequently
Colonic obstruction	Rarely	Frequently
Response to antibiotics	No	Yes
Recurrence after surgery	No	Yes
ANCA-positive	Frequently	Rarely
ASCA-positive	Rarely	Frequently
Malignant potential	High	Relatively low

## Endoscopic

Rectal sparing	Rarely	Frequently
Continuous disease	Yes	Occasionally
"Cobblestoning"	No	Yes
Pseudopolyps	Common	Rare
Granuloma on biopsy	No	Occasionally

## Radiographic

Small bowel significantly abnormal	No	Yes
Abnormal terminal ileum	Occasionally	Yes
Segmental colitis	No	Yes
Asymmetric colitis	No	Yes
Stricture	Occasionally	Frequently

**Note:** ANCA, antineutrophil cytoplasm antibody; ASCA, anti-*Saccharomyces cerevisiae* antibody.

Correction for lec 16 by my friend ahmad nazal, on page 16, TIPS is the short for transjugular intrahepatic portosystemic shunt.

### Sources

- Davidson's P&P of medicine 21<sup>st</sup> edition
- Kumar & Clark's Clinical Medicine, 7th Edition
- Harrison's Principles of Internal Medicine - 17ed
- First Aid for the Internal Medicine Boards 2nded

**This work is dedicated to my group, the best group ever "B1 "**

**Done by:**

Maen K. Abu Househ